

# Endoscopic Septoplasty: Advantages and Disadvantages

<sup>1</sup>SS Suligavi, <sup>2</sup>MK Darade, <sup>3</sup>BD Guttigoli

<sup>1</sup>Assistant Professor, Department of ENT and Head and Neck Surgery, S Nijalingappa Medical College and HSK Hospital and RC, Navangar Bagalkot, Karnataka, India

<sup>2</sup>Professor and Head, Department of ENT and Head and Neck Surgery, S Nijalingappa Medical College and HSK Hospital and RC, Navangar Bagalkot, Karnataka, India

<sup>3</sup>Professor, Department of ENT and Head and Neck Surgery, S Nijalingappa Medical College and HSK Hospital and RC Navangar Bagalkot, Karnataka, India

**Correspondence:** Shashidhar S Suligavi, Assistant Professor, Department of ENT and Head and Neck Surgery, S Nijalingappa Medical College and HSK Hospital and RC, Navangar Bagalkot, Karnataka-587102, India, Phone: 09448964141 e-mail: ssshshidhar@yahoo.co.in

## Abstract

Our study was conducted to assess the advantages and disadvantages of use of endoscopes use in septoplasty. Hundred patients with symptomatic deviated nasal septum were randomly divided into endoscopic septoplasty (ES) group and conventional septoplasty (CS) group of 50 patients each. The two groups were compared for technique, improvement in symptoms and complications. The postoperative symptoms and complications were significantly less in ES group due to better visualization and minimal dissection.

**Keywords:** Deviated nasal septum, endoscopic septoplasty.

## INTRODUCTION

Deviated nasal septum is one of the most common causes for nasal block. It also causes contact headache, epistaxis, infection of paranasal sinuses and middle ear diseases due to eustachian tube blockage. With the introduction of endoscope, septoplasty has become easier and it provides direct approach to septal deformity. Durr DG concluded that endoscope allows improved visualization and correction of posterior septal deformity and middle meatal abnormalities simultaneously.<sup>1</sup> Giles GC et al showed that it can be done in a relatively shorter time and limit the extent of dissection to the area of pathology.<sup>2</sup> Nayak DR et al compared ES and CS groups and suggested that endoscope assisted septoplasty is a viable alternative to conventional septoplasty and safe.<sup>3</sup> The present study was conducted to compare the advantages and disadvantages of endoscopic septoplasty and outcomes of two groups.

## MATERIAL AND METHODS

The current study was conducted in the Department of Otorhinolaryngology and Head Neck Surgery, S Nijalingappa Medical College and HSK Hospital and RC between 2005 and 2009. A total of 100 patients above 18 years of age with symptomatic DNS were randomly divided into two

groups of 50 each. Anterior and Posterior rhinoscopy were done in all patients to rule out other pathologies. All patients underwent complete hemogram and X-ray PNS; Water's view. CT scan of nose and PNS was done in selected patients. After complete evaluation, ES group (n = 50) underwent endoscopic septoplasty and CS group (n = 50) underwent conventional septoplasty under local anesthesia. In ES group, 27 patients had other procedures like inferior turbinate cauterization (ITC), FESS and endoscopic DCR whereas in CS group 11 patients had ITC which is shown in Table 1.

**Table 1:** Various procedures done in both groups

Surgery	No. of cases	
	CS	ES
Septoplasty	50	50
ITC	11	21
FESS	0	10
Endonasal DCR	0	9

## ENDOSCOPIC SEPTOPLASTY PROCEDURE

The 0 and 30 (4 mm diameter) endoscopes were used for the procedure. Xylocaine 2% with adrenaline was infiltrated on both sides of septum. An incomplete incision was made at caudal end of septum in its lower half in most cases

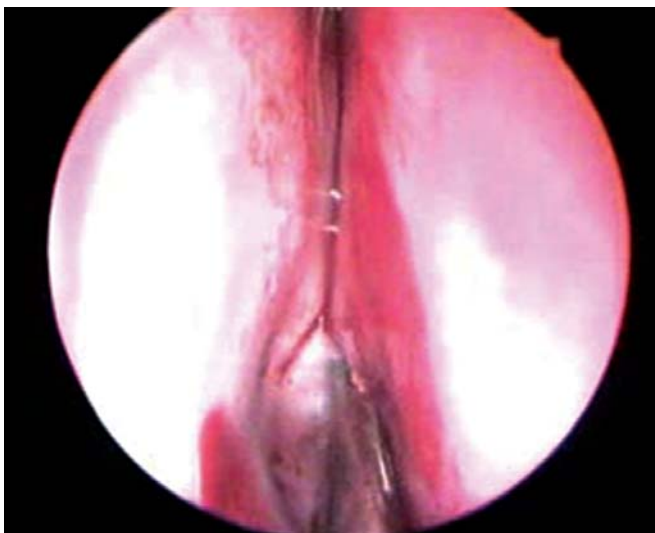
except when there was a caudal dislocation or anterior buckling, then hemitransfixation incision was used. Flaps were elevated only in the area of pathology (Fig. 1). In case of cartilaginous deviation, cartilage was incised caudal to deviation and excised (Fig. 2). If there was a bony deviation, the bonycartilaginous junction was broken (Fig. 3) and deviation was excised (Fig. 4). In case of isolated spur, incision was taken on the spur itself parallel the floor and flaps were elevated above and below the spur. Nasal cavities were packed with antibiotic soaked light ribbon gauze packs. In Conventional Septoplasty, Cottle's maxilla-premaxilla approach was used.

The packs were removed after 24 hours in ES group and after in 48 hours in CS group. All patients were followed

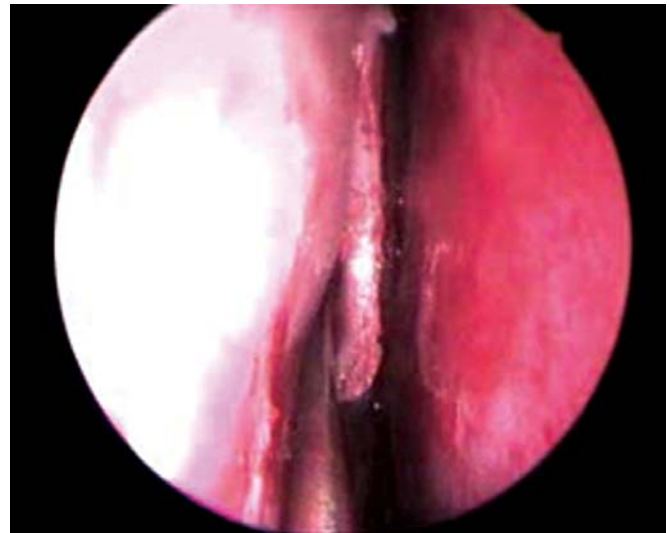
up at 1st, 4th and 12th week. Final assessment was done at 6th month with the help of endoscope in all patients. Results were assessed using Z test and p-value and statistical significance was obtained between two groups.

## RESULTS

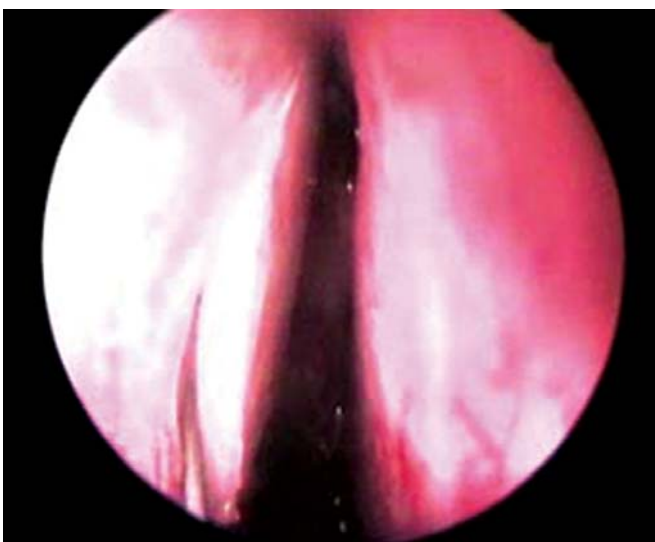
It was noted that maximum number of patients were between 21 years to 30 years of age; 34 (68%) in CS group and 30 (60%) in ES group. CS group had 41 males and 9 females and ES group had 40 males and 10 females. Comparison of relief in symptoms done after 6th month postoperatively is shown in Table 2. Nasal block, headache, nasal discharge and hyposmia were significantly less in ES



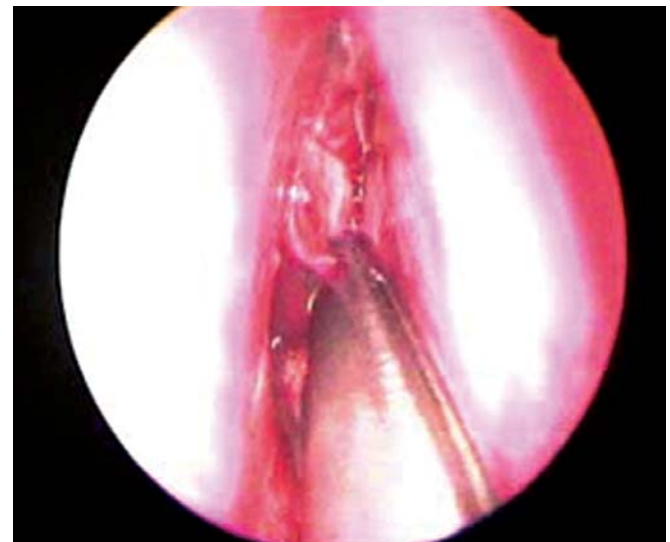
**Figure 1:** Elevation of septal flaps



**Figure 3:** Disarticulation of bony cartilaginous junction



**Figure 2:** Incision of cartilage caudal to deviation



**Figure 4:** Excision of deviated bony septum

**Table 2:** Comparison of relief in symptoms in both groups (after 6 months)

Symptoms	CS		ES		ST SG
	Postop/Preop	Percent age of benefit	Postop/Preop	Percent age of benefit	
Nasal block	44/50	88%	48/50	96%	S
Nasal discharge	10/11	90%	13/13	100%	S
Headache	24/28	85.71%	34/36	94.4%	S
PND	13/14	92.8%	17/18	94.4%	NS
Hyposmia	2/3	66.6%	4/4	100%	S

STSG: Statistical significance, S: Significant, NS: Not significant.

group and there was no statistical significance between two groups for postnasal discharge. Complications in both groups (intraoperative and postoperative) are shown in Table 3. Hemorrhage, mucosal tear and synechiae were significantly more in CS group. Other complications like septal hematoma, abscess and external deformities were not reported in both the groups.

**Table 3:** Comparison of complications (intra and postoperative) in both groups

Complications	CS	ES	STSG
Hemorrhage	13	7	S
Mucosal tear	18	10	S
Synechiae	10	3	S
Residual deformities	7	8	NS
Septal hematoma	0	0	
External deformity	0	0	

STSG: Statistical significance, S: Significant, NS: Not significant.

## DISCUSSION

Various methods have been described like submucosal resection (SMR) popularised by Killian,<sup>4</sup> Galloway's removal of entire nasal cartilage and replacement as a single autograft<sup>5</sup> and Cottle's refined maxilla-premaxilla technique.<sup>6</sup> Entry of endoscopes into the field of Otorhinolaryngology has initiated many efforts to use them in septoplasty. It is more effective with minimal manipulation and lateral wall abnormalities can be dealt with simultaneously. Durr DG conducted a study in 47 patients and evaluated nasal block, rhinorrhea and pain and found satisfactory results in 80% cases with endoscope.<sup>1</sup> In a study by Arunachalam PS and Kitcher E, nasal block and facial pain were relieved in 74% and 72% patients respectively.<sup>7</sup> Harley et al described significant improvement in headache and nasal block in ES group compared to CS group.<sup>8</sup> It is in concordance with our study. Hwang et al showed that complication rate was 5% in endoscopic septoplasty.<sup>9</sup> It is lesser than in our study.

The primary advantage of the endoscopic septoplasty is the ability to reduce the morbidity by limiting the dissection to the area of deviation. Other advantages include better visualization and accessibility to remote areas, improved surgical transition between septoplasty and sinus surgery. It minimises the intra- and postoperative bleeding and mucosal tears because of proper elevation of flaps. Endoscope is particularly helpful in revision septoplasty. It facilitates realignment by precise shaving/wedge resection of cartilage. It effectively addresses the pathologies of turbinates, contact areas and discharge in middle meatus better than conventional method. Limited resection allows minimal nasal packing for lesser duration hence lesser immediate and late postoperative pain.

## CONCLUSION

Endoscope has its own limitations like loss of binocular vision, need for frequent cleaning of the tip and needs more expertise, even then it is an attractive and viable alternative to traditional headlight septoplasty. This approach is safe, effective and ultraconservative. This study shows superiority of endoscopic septoplasty in managing deviated nasal septum both subjectively and objectively. It is an effective teaching and motivation tool and helps in objective documentation. Our study concludes that combined approach is ideal—Conventional approach for anterior most part and Endoscopic approach for the inaccessible middle and posterior parts of nasal septum.

## REFERENCES

1. Durr DG. J Otolaryngol. Endoscopic septoplasty: Technique and outcome 2003;32(1):6-11.
2. Giles WC, Gross CQ, Abraham AC, Greene WM, Avner TG. Endoscopic septoplasty. Laryngoscope Dec 1994;104(12):1507-09.

3. Dipak Ranjan Nayak, R Balakrishnan, K Deepak Murthy. An endoscopic approach to the deviated nasal septum: A preliminary study. *JLO* 1998;112:934-39.
4. Killian G. Die submucosae fensterresektion der Nasenscheidewand: *Archiv fur Laryngologie und Rhinologie* 1904;16:362.
5. Galloway T. Plastic repair of the deflected nasal septum. *Archives of Laryngology* 1946;44:141.
6. Cottle MH, Fisher GG, Gaynon IE. The maxilla: Premaxilla approach to extensive nasal septum surgery. *Archives of Otolaryngology* 1958;68:301.
7. Aranachlam PS, Kitcher E, Gray J. Nasal septal surgery: Evaluation of symptomatic and general health outcomes. *clinical otolaryngol* 2001;26(5):367-70.
8. Harley DH, Powtzky ES, Duncavage J. Clinical outcomes for the surgical treatment of sinonasal headache. *Otolaryngol Head Neck Surg* 2003;129,217-21.
9. Hwang PH, Robert B Mc Langhlin, Donal C Lanza and David W Kennedy. Endoscopic septoplasty: Indications, technique and results. *Otolaryngology: Head and Neck Surgery* 1999;20(5); 678-82.